

# Marginal bone level around iSy implants placed in healed alveolar ridges with delayed restoration in comparison with post-extraction insertion and immediate load, retrospective analysis at 12 months

*Maturo P. Rome, Italy\**

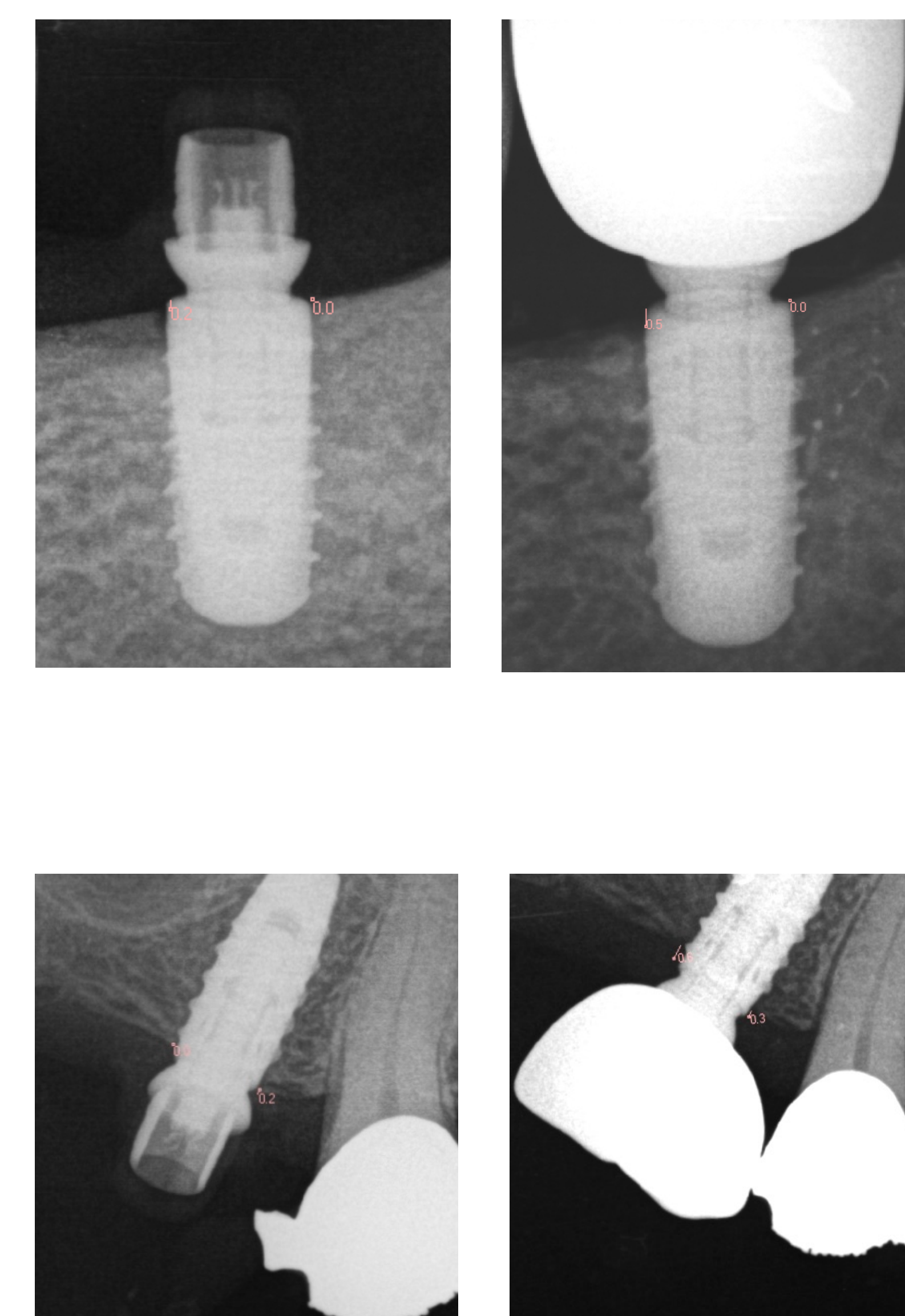
The aim of this retrospective study is to report, in a period of 12 months, the radiologic marginal bone level outcome of patients treated with single tooth iSy implants when used in healed alveolar ridge with conventional loading protocol, in comparison with an immediate loading protocol in post-extraction sites.

**Materials and methods:** 16 patients in need of a single-tooth replacement received iSy implants.

In Group A 8 iSy implants were placed in healed ridges, with transgingival healing using iSy healing cap and restored with delayed load and restoration.

In Group B 8 iSy implants were placed immediately into fresh extraction sockets without flap elevation and restored with immediate non functional loading by using a provisional crown bonded to the multifunctional cap and then snapped onto the implant base. The final restorations were made in all cases after 3 months from the surgery with a screw retained hybrid abutment crown (zirconia bonded to the titanium implant base).

The Marginal bone level relative to the implant reference point was recorded at implant placement and after 12 months following surgery using standardized periapical radiographs. All of the periapical radiographs were acquired by a digital system using the photostimulable phosphor (PSP) plate (Kodak CS 7600, Carestream Health, Rochester, NY). Measurements were made on the mesial and distal sides of each implant, calculated as vertical distance between crestal bone level and implant neck using Kodak Dental Imaging software (Kodak Dental Imaging Software 6.12.32.0), measurements were performed twice for each recording and by the same operator.



**Results:** The mean change in marginal bone loss (MBL) after 1 year of implant placement was  $0.31 \pm 0.22$  mm in extraction sockets and  $0.29 \pm 0.20$  in healed ridges.

	Post-extraction				Conventional Loading				
	Base Line		1 year		Base Line		1 year		
Pat.#	Mesial	Distal	Mesial	Distal	Pat.#	Mesial	Distal	Mesial	Distal
1pe	2,3	0,9	1,7	1,4	1c	0,1	0,1	0	0
2pe	1,6	1,2	0,3	0,2	2c	0,5	0,4	0,3	0
3pe	-0,1	0,1	0	0,3	3c	0,2	0	0,5	0
4pe	-0,7	0	-0,9	0,2	4c	0,3	-0,2	-0,5	-0,7
5pe	0,6	0,7	0,4	0,5	5c	0,8	0,4	0,3	0,4
6pe	1,6	1,4	1,6	0,9	6c	0,2	0	-0,3	-0,6
7pe	1,2	0,7	0,6	-0,2	7c	0,8	0,2	0,7	-0,1
8pe	0,1	0,3	0	-0,1	8c	0,6	0,4	0,2	0
<b>Result</b>	0,825	0,6625	0,4625	0,4	<b>Result</b>	0,4375	0,1625	0,1125	-0,0875
<b>Average</b>		0,74375		0,43125	<b>Average</b>		0,3		0,0125
<b>Delta</b>				<b>0,3125</b>	<b>Delta</b>				<b>0,2875</b>

**Conclusions:** Within all the limitations of this study, responses of local bone to immediately loaded iSy implants placed in extraction sockets or in healed ridges with delayed load were similar after one year. Immediate restoration technique by using iSy titanium implant base as abutment and with snapped multifunctional cap (without cement) placed in post-extraction single implants seems not to have influence on marginal bone around iSy implants as compared to conventional delayed surgery and loading in a period of one year.

Disclosure: the author declare non conflict of interest

\* University of Rome "Tor Vergata" - Italy  
Department of Experimental Medicine and Surgery

## References

- Berberi AN, Sabbagh JM, Aboushelib MN, Noujeim ZF, Salameh ZA. A 5-year comparison of marginal bone level following immediate loading of single-tooth implants placed in healed alveolar ridges and extraction sockets in the maxilla. *Front Physiol.* 2014 Jan 31;5:29
- Sanz-Sánchez I, Sanz-Martín I, Figuero E, Sanz M. Clinical efficacy of immediate implant loading protocols compared to conventional loading depending on the type of the restoration: a systematic review. *Clin Oral Implants Res.* 2015 Aug;26(8):964-82. doi: 10.1111/clr.12428. Epub 2014 Jun 11. Review
- Felice P, Pistilli R, Barausse C, Trullenque-Eriksson A, Esposito M. Immediate non-occlusal loading of immediate post-extractive versus delayed placement of single implants in preserved sockets of the anterior maxilla: 1-year post-loading outcome of a randomised controlled trial. *Eur J Oral Implantol.* 2015 Winter;8(4):361-72.
- Berberi AN, Noujeim ZN, Kanj WH, Mearawi RJ, Salameh ZA. Immediate placement and loading of maxillary single-tooth implants: a 3-year prospective study of marginal bone level. *J Contemp Dent Pract.* 2014 Mar 1;15(2):202-8.